

## An Explosive Decompression Accident

J. C. Giertsen, M.D., E. Sandstad, M.D., I. Morild, M.D., G. Bang, M.D.,  
A. J. Bjersand, M.D., and S. Eidsvik, M.D.

Four divers in a compression chamber system were suddenly decompressed from 9 atm to 1 atm. One of the divers was about to close the door between the chamber system and the trunk when the accident happened. He was shot out through the door and severely mutilated. The three others died on the spot. The autopsy results are described. The most conspicuous finding was large amounts of fat in the large arteries and veins and in the cardiac chambers, as well as intravascular fat in the organs, especially the liver. This fat can hardly have been embolic, but must have "dropped out" of the blood in situ. It is suggested that the boiling of the blood denatured the lipoprotein complexes, rendering the lipids insoluble.

**Key Words:** Decompression, explosive—Decompression, accident.

On 5 November 1983, an accident resulting in the sudden decompression of four divers from a pressure of 9 atm to 1 atm occurred on board the Norwegian oil rig Byford Dolphin in the North Sea.

### THE ACCIDENT

The situation just before this accident occurred was as follows (Fig. 1). Compression chambers 1 and 2 were connected via a trunk to a diving bell. This connection was sealed by a clamp operated by two tenders (Dt 1 and Dt 2), who themselves were experienced divers. A third chamber was in fact connected to this system, but was not involved. On this day, divers 1 (35 years old) and 2 (38 years old) were resting in chamber 2 at a pressure of 9 atm. The diving bell with divers 3 (29 years old) and 4 (34 years old) had just been winched up after a dive and joined to the trunk. Leaving their wet gear in the trunk, the divers had then crept through the trunk into chamber 1. The normal procedure would have been to (a) close the bell door, (b) slightly increase the bell pressure to seal this door tightly, (c) close the door between the trunk and chamber 1, (d) depressurize the trunk to 1 atm, and (e) open the clamp to separate the bell from the chamber system.

Operations a and b had been completed and diver 4 was about to carry out operation c when, for some inexplicable reason, one of the tenders opened the clamp. The result was a free communication between the chamber system with a pressure of 9 atm and the surroundings with a pressure of 1 atm. A tremendous blast shot from the chambers through the trunk, pushing the bell away and hitting the two tenders. The one who had opened the clamp died, and the other was severely injured. Unfortunately, the dead tender was not sent to us for autopsy.

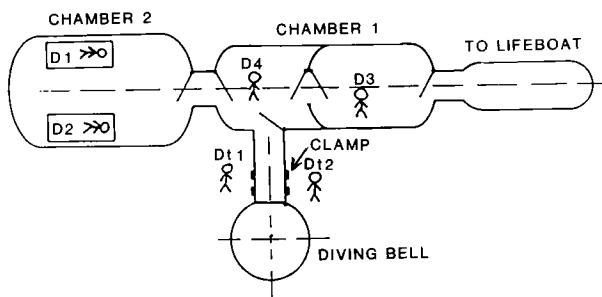
Figure 2 shows how diver 4 probably was about to close the chamber door when the accident occurred. The chamber opening was 60 cm in diameter. Unfortunately, the door jammed (Fig. 3) so firmly that it later had to be cut loose with an acetylene burner. Diver

---

From the University of Bergen, The Gade Institute, Bergen, Norway. Professor of Forensic Medicine (J.C.G.); Acting Head, The Gade Institute, Section of Neuropathy (I.M.); Professor of Oral Pathology (G.B.); Assisting Head, Haukeland University Hospital, Department of Radiology (A.J.B.); Captain of the Royal Norwegian Navy, Senior Diving Medical Officer (S.E.).

A preliminary version of this paper was given by Giertsen at the 10th Meeting of the International Association of Forensic Sciences, Oxford, England, 19 September 1984.

Address correspondence and reprint requests to J. Chr. Giertsen, M.D., University of Bergen, The Gade Institute, Department of Forensic Medicine, 5021 Bergen, Norway.



**FIG. 1.** Sketch of the compression system and the involved persons' position just before the accident occurred.


4 was shot out through the opening and completely disintegrated. Parts of him were found scattered about the rig. One part was even found lying on the derrick, 10 m above the chambers!

The other three divers in the chambers died on the spot, probably instantaneously (Figs. 4–6).


### POSTMORTEM EXAMINATIONS

The remains of diver 4 were sent to us in four plastic bags (Fig. 7). All parts showed fractures and wounds. The fractures of the long bones were of transverse as well as short and long oblique types, the fracture lines being more irregular than usual, with small, splintered fragments.

The scalp with long, blond hair was present, but the top of the skull and the brain were missing. The base of the skull was a collection of tiny bone fragments only. The soft tissues of the face were found, however, completely separated from the bones (Fig. 8). The left upper arm had been separated from the body just below the shoulder joint. The right upper arm was torn to pieces, but still attached to the body. Both hands had been separated from the lower arms. The right thigh, leg, and foot were missing, but the knee joint was found. The left thigh had been separated from the pelvis just



**FIG. 2.** The probable position of diver 4 about to close the chamber door.



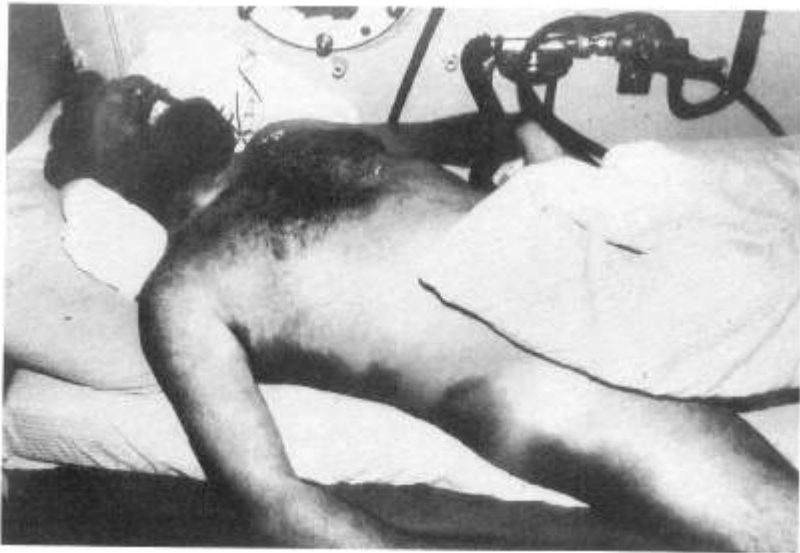
**FIG. 3.** The approximate position of the jammed chamber door.

below the hip joint. The pelvis itself had been divided into three parts. To one of these parts, a small segment of the small bowel was attached. The penis was present, but invaginated. The soft tissues of the abdomen and the back had been cut straight through at a level about midway between the umbilicus and the pelvis, and thus had been separated from the pelvis. These soft tissues formed an empty sack. From above, one could look down through the larynx. All the thoracic and abdominal organs had been expelled, except the trachea and a fragment of the small bowel (Fig. 9). Even the spinal column (Fig. 10) and most of the ribs had been expelled. The liver had been found somewhere on the deck. It was complete, as if dissected out of the body.

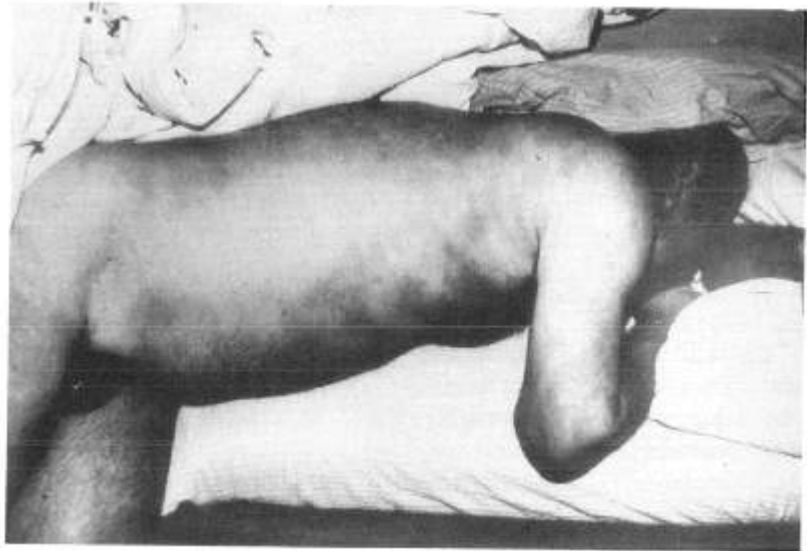
The autopsy on divers 1, 2, and 3 were performed 3 days after death, and the findings were essentially the same in all three cases. The rigor mortis was unusually strong. The hypostases were light red, and in two cases there were numerous petechial hemorrhages in the livores.

All the organs showed large amounts of gas in the blood vessels, and scattered hemorrhages were found in the soft tissues. One of the divers had a large subconjunctival bulla (Fig. 11).

The lungs were edematous (1.250 g, 1.350 g, and 1.600 g) with bandlike subpleural hemorrhages corresponding to the intercostal areas (Fig. 12) and with a number of subpleural bullae (Fig. 13). The cut surface showed intrapulmonary hemorrhages.



**FIG. 4.** Diver 1, who died on the spot.




**FIG. 5.** Diver 2, who died on the spot.



**FIG. 6.** Diver 3, who died on the spot.

FIG. 7. The remains of diver 4.



The livers were fairly large and hyperemic (1,900 g, 2,140 g, 2,500 g).

The blood vessels of the stomach formed a prominent, dark network not unlike the findings in putrefied bodies (Fig. 14).

In the cardiac chambers and in the great vessels around the heart, both arteries and veins, large amounts of free fat were found (Fig. 15). This fat was mixed with gas bubbles, and looked like sizzling butter on a frying pan.

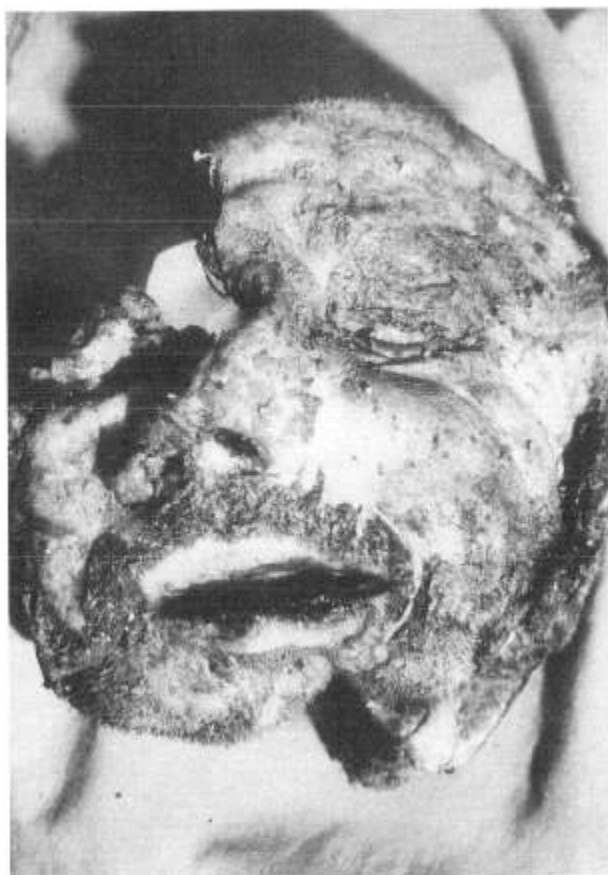

FIG. 8. The soft tissues of the face of diver 4.

Microscopic examination showed free fat (Scarlet Red stain) in the blood vessels of the parenchymatous organs, especially in the liver but also to some extent in the other organs (Figs. 16 and 17).

No traces of alcohol or drugs were found.

#### NEUROPATHOLOGIC EXAMINATION

The brains and the spinal cords from divers 1, 2, and 3 were examined. The brains were very pale, and the blood vessels were filled with gas (Fig. 18). In the major blood vessels, a yellow substance looking like fat was present. In the brain from diver 3, gross cystic areas were found in the putamen, the internal capsule, and the dentate nuclei. Otherwise, neither the brains nor the spinal cords showed any old or recent pathological lesions.

Microscopic sections from all levels of the brains and the spinal cords revealed multiple cystic areas without any vital reaction, especially near blood vessels (Fig. 19). These were interpreted as air bubbles. A Scarlet Red stain for fat was positive in some sections (Fig. 17).

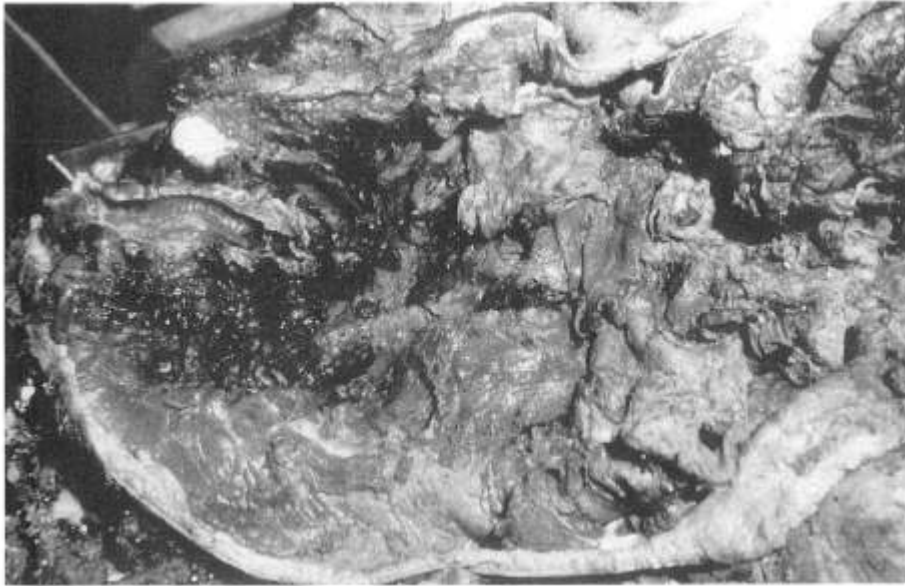No old degenerative changes were found.

#### SKELETAL EXAMINATION

A roentgenologic examination was performed of the bones of the shoulder, the hip, and the knee joints in search for signs of aseptic bone necrosis (1). Approximately 2-mm-thick sections were cut from suspicious lesions in the bones with a band saw equipped with a diamond saw blade. The sections were fixed in 4% neutralized formalin and decalcified. Thereafter, they were embedded in paraffin, cut at 4  $\mu$ m and stained with haematoxylin and eosin.

In diver 1, no suspicious changes were found.

In diver 2, an area of increased density of the bone structure  $\sim$ 10 mm in diameter, was present in the neck of the right free dissected femoral head (Fig. 20). This

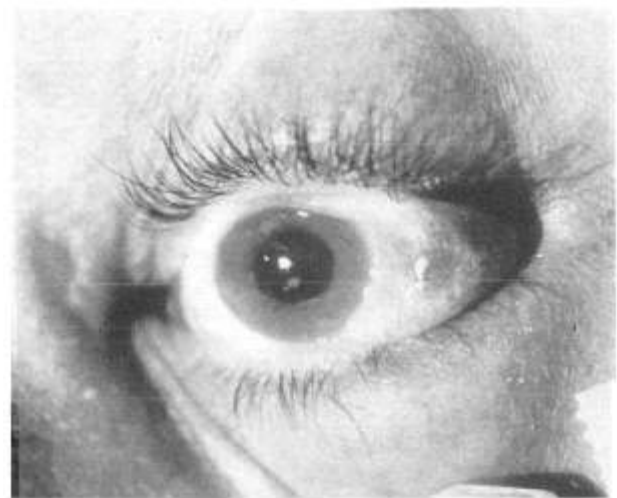

**FIG. 9.** The opened thoracoabdominal cavities of diver 4. Trachea to the left. Remains of the small bowel, otherwise empty.

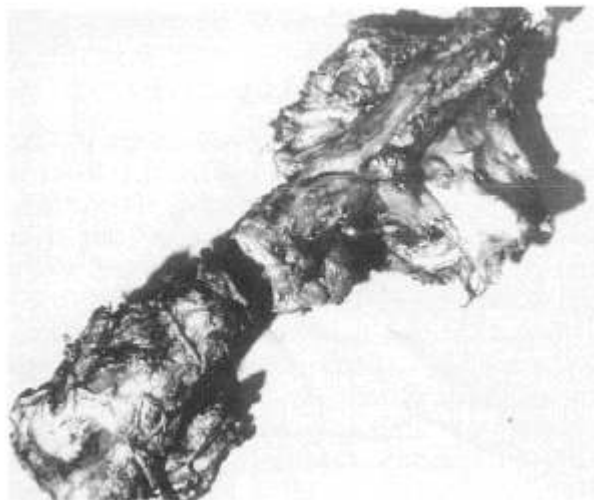
area was cut out. Grossly, no pathologic changes were observed. Microscopic examination revealed some thickened trabeculae due to the apposition of new bone. In some areas of the original trabeculae, the lacunae appeared empty (Fig. 21). This was interpreted as an aseptic bone necrosis.

In diver 3, a  $22 \times 12$ -mm area of intense sclerosis with a central lucency was found in the right femoral neck. Roentgenologically it looked like a small osteoid osteoma. Grossly, a sclerotic zone with a central empty area was observed. Microscopic examination showed a circular area of mature, lamellar bone circumscribing a small empty area. There was no necrosis or inflammation. This was interpreted as a nonspecific lesion.

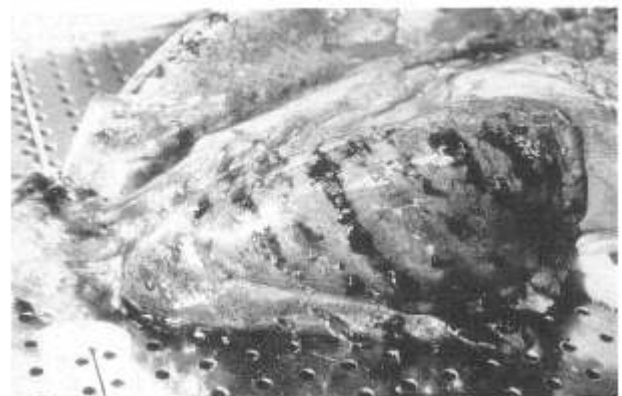In diver 4, no roentgenologically suspicious changes were found.



**FIG. 11.** Subconjunctival bulla. Diver 1.

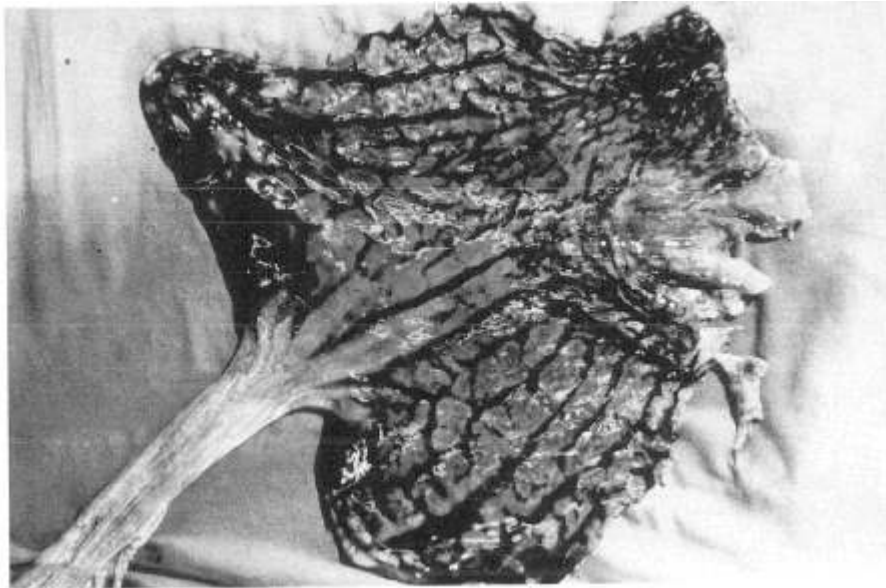
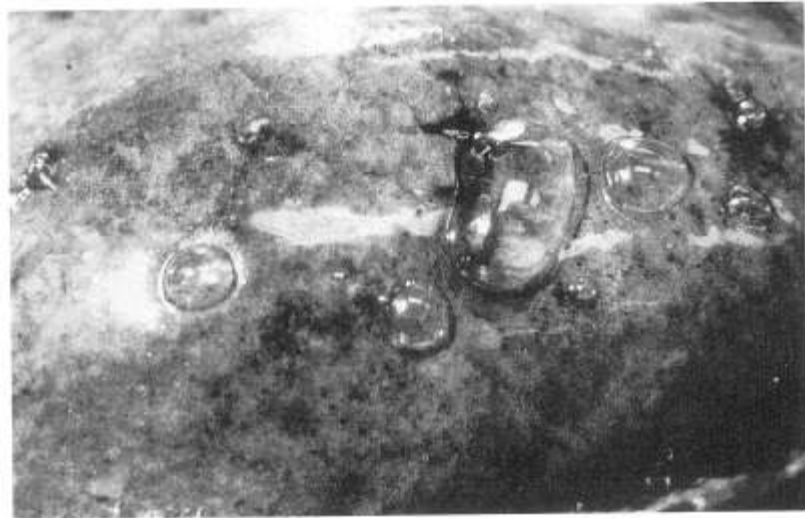

**FIG. 10.** Part of the spinal column of diver 4.

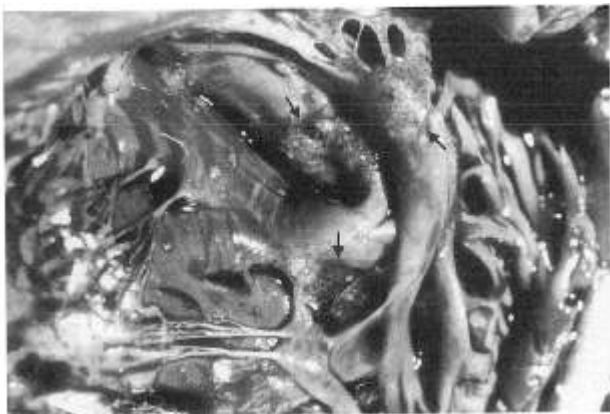

**FIG. 12.** Bandlike subpleural hemorrhages corresponding to the intercostal areas. Diver 1.

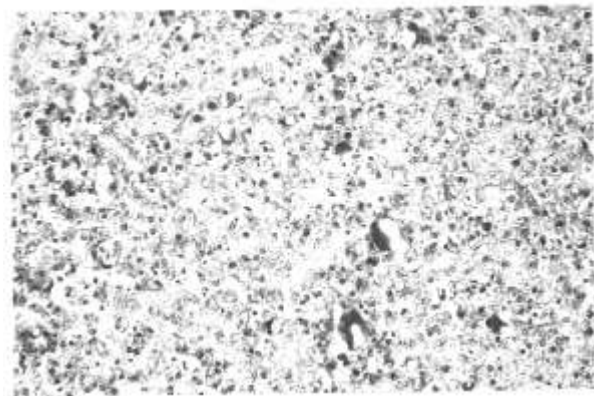
**FIG. 13.** Subpleural bullae. Diver 1.



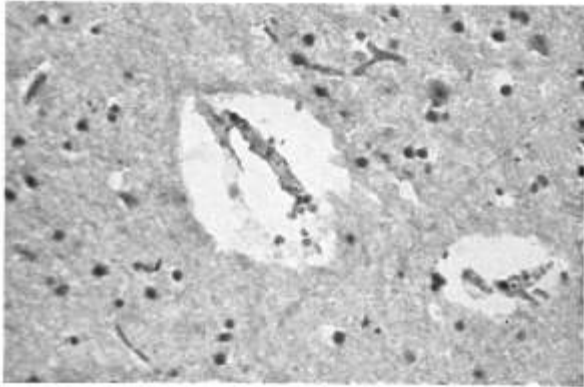
**FIG. 14.** Stomach with prominent blood vessels. Diver 1.



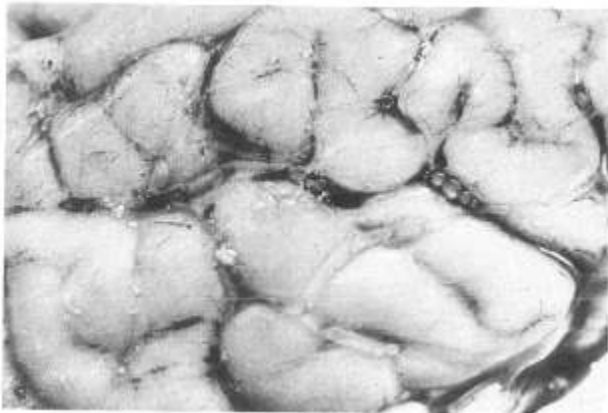
**FIG. 15.** Cardiac chamber with large amounts of free fat adhering to the papillary muscles (arrows). Diver 1.



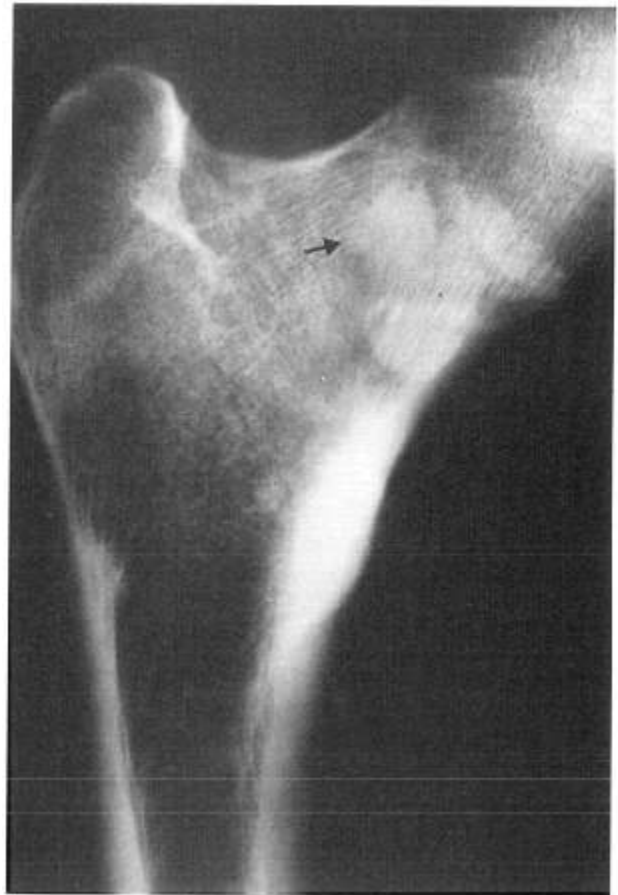**FIG. 16.** Liver with positive fat stain (Scarlet Red).  $\times 67$ .



**FIG. 17.** Cerebral vessel with positive fat stain (Scarlet Red).  $\times 178$ .



**FIG. 18.** Surface of brain with gas-filled vessels.




**FIG. 20.** Dysbaric bone necrosis in right femoral neck (arrow).

**DISCUSSION**

It was tragic that the door between the chambers and the trunk jammed as it did. If the construction of the hinge mechanism had been such that the door

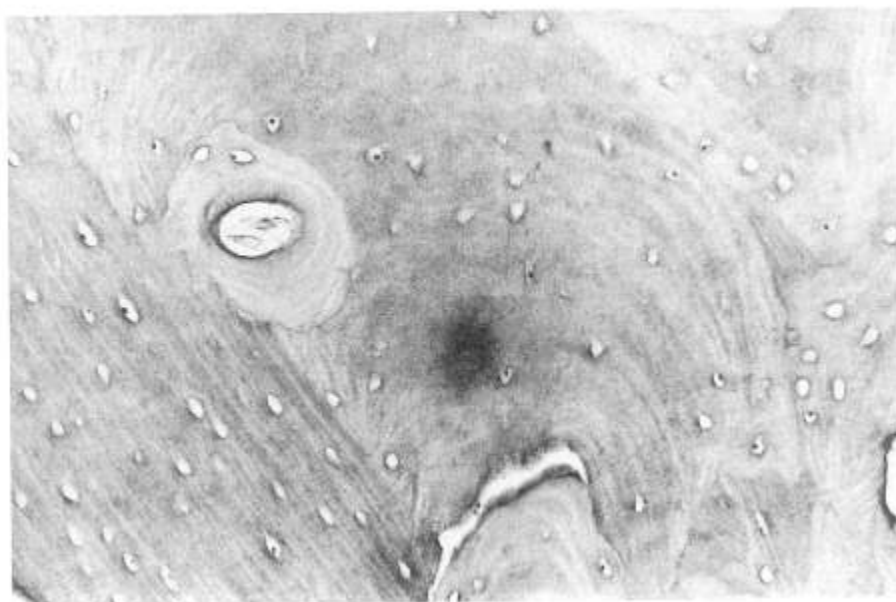
would have closed automatically in case of an external pressure drop, these four divers and the tender might have survived!

The fate of diver 4 clearly demonstrates the tremendous force released in an accident like this. He was



**FIG. 19.** Gas bubbles in the brain.  $\times 110$ .

**FIG. 21.** Microscopic appearance of the dysbaric bone necrosis shown in Fig. 20.  $\times 200$ .



undoubtedly mutilated when he was shot out through the small opening left by the jammed chamber door. However, the expulsion of all internal organs from the thoracoabdominal "sack," including the spinal column and the ribs, suggests that he also must have exploded. Unfortunately, we were not called to the scene. We might then have found more organs from this diver. On the other hand, the locality was such that parts of him may have been blown straight into the sea.

Nonfatal decompression incidents may lead to injuries, especially to the central nervous system and the bones (2). In the central nervous system, the spinal cord particularly is mostly affected. Small infarcts may arise, with secondary ascending and descending tract degeneration, and healing with gliosis. In the three divers examined in our case, no such lesions were found. In the bones, aseptic or dysbaric necrosis may be found. In one of our divers, one possible lesion was found. Thus, in these divers, we could not demonstrate any sequelae of previous serious decompression incidents.

The most conspicuous finding in this case was the presence of large amounts of free fat in the cardiac chambers and the great vessels, as well as in the smaller vessels of both the systemic and the pulmonary circulation. The occurrence of fat embolism in decompression accidents is well known (3,4). However, an embolus is particulate matter transported by the bloodstream from one part of the body to another. In our cases, the blood must have begun to boil instantaneously, leading to an instantaneous and complete stop of the circulation. The fat cannot have been transported from anywhere, but must have "dropped out" from the blood in situ. Possibly, the boiling of the blood led to a denaturation of the lipoprotein complexes,

rendering the lipids insoluble. If this is true, it seems appropriate to discontinue the use of the term "fat embolism" in decompression accidents and replace it with, for example, "fat precipitation." It also seems that decompression fat precipitation may have a different etiology from traumatic fat embolism.

An expert committee investigated this accident and concluded that it was due to a human error. It is not clear whether the tender who opened the clamp before the trunk was depressurized did so by order of the diving supervisor or on his own initiative.

In 1982, "Det norske Veritas" had issued revised regulations regarding the technical arrangement of diving spreads. One requirement was that the trunk should be impossible to open while it is pressurized. The Byford Dolphin was, however, not rebuilt because the regulations were not retroactive. The expert committee recommended that the system on board the rig should be rebuilt according to the new regulations. It was further suggested that the doors between the various chambers of such a system should be kept closed during an operation like this, or a device should be installed to ensure that they would close automatically in the case of a pressure drop. □

## REFERENCES

1. Decompression Sickness Central Registry and Radiological Panel. Aseptic bone necrosis in commercial divers. *Lancet* 1981;1: 384-8.
2. Calder IM. Dysbarism. *Forensic Sci Int* 1986;30:237-66.
3. Hendry WT, Childs CM, Proctor DM. The offshore scene and its hazards. In: Mason JK, ed. *The pathology of violent injury*. London: Edward Arnold, 1978:289-317.
4. Mason JK. *Aviation accident pathology*. London: Butterworths, 1962:134-74.